

Ophthalmomyiasis Externa: A Case Report

SEEMA BOSE, SANTOSH SAINI, REKHA BARAPATRE, STEPHEN MATHEW

ABSTRACT

Ophthalmomyiasis externa results from the infestation of the conjunctiva by the larval form of dipterous flies. Only a few cases of Ophthalmomyiasis externa which were caused by the larva of *Oestrus ovis* had been previously reported from India. Here, we are discussing a case of Ophthalmomyiasis externa which was

caused by the larvae of *Oestrus ovis* in a 10-year old child. A prompt diagnosis and management of the condition saved the patient from a potential serious outcome. The importance of hand hygiene and the maintenance of sanitation have also been illustrated.

Key Words: Ophthalmomyiasis, *Oestrus ovis*, Slit lamp examination

INTRODUCTION

Myiasis, the infestation of humans with dipterous fly maggots, is common in the tropical countries with a large fly population [1].

Ophthalmomyiasis refers to the infestation of the eye and the ocular adenexa by the larval form of dipterous flies. Based on the parts of the eye which are involved, there are three types of Ophthalmomyiasis. The first type is the Ophthalmomyiasis externa in which only conjunctiva is involved. This condition, if it is not managed in time, can lead to two other of its dreaded types, such as Ophthalmomyiasis interna (the larvae invade the ocular globe and they are found in the sub-retinal space and the vitreous cavity) and orbital Ophthalmomyiasis (invasion of the orbit) [2,3,4].

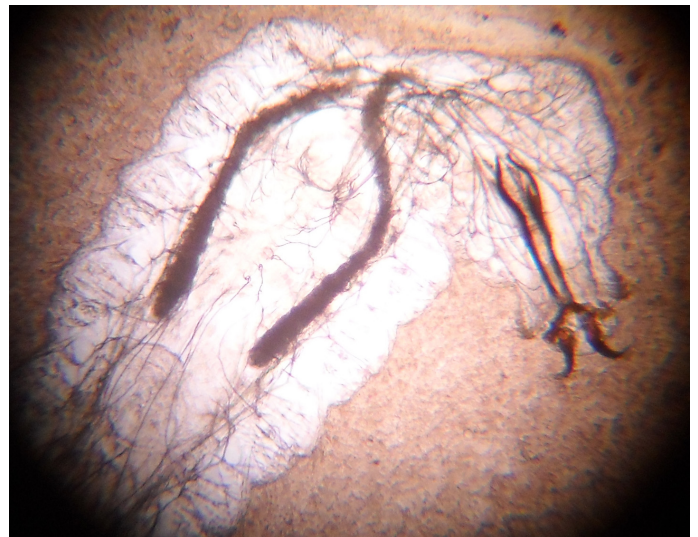
Ophthalmomyiasis externa is mainly caused by sheep bot fly (*Oestrus ovis*). Therefore, this is more common in the farming communities [4]. Very few cases of Ophthalmomyiasis externa which were caused by *Oestrus ovis* infestation have been reported so far from India. Here, we are reporting a case of Ophthalmomyiasis externa in a 10-year old male child who had no known history of contact with farm animals.

CASE REPORT

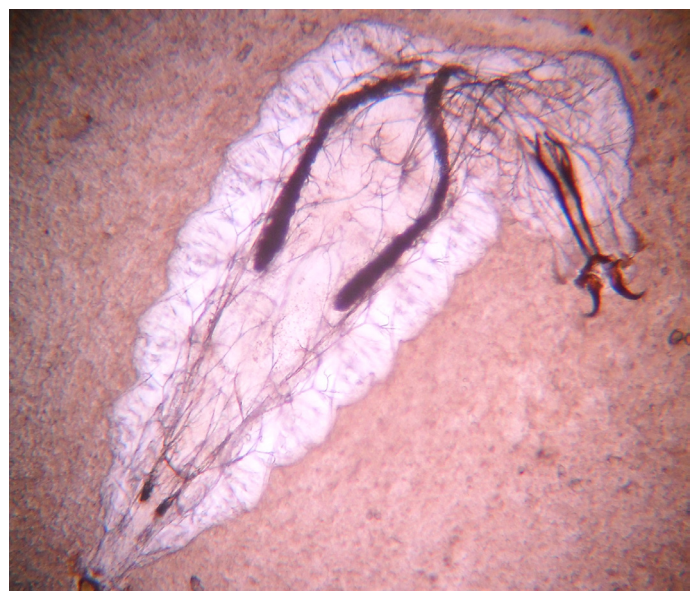
A 10-year old male child presented to the Outpatients Department of Ophthalmology with complaints of pain, irritation, foreign body sensation and watering of the right eye for one day. He had been apparently healthy before, when he complained that something had entered into his right eye, when he was playing in a field. After that, he suffered from irritation, pain and watering from the right eye. He also complained of fever which was associated with chills.

The patient was not in close contact with animals like sheep, goats and cows. There was no significant medical history.

An ophthalmic examination revealed a visual acuity of 6/6 in both the eyes. The ocular position was normal and the ocular movements were full and free in all the directions. There was bilateral focal symmetry. The intraocular pressure was normal in both the eyes. The lacrimal sac was clinically patent. The conjunctiva was congested, with profuse lacrimation in the right eye.



[Table/Fig-1]: Showing pair of sharp dark brown oral hooks of larva of *Oestrus ovis*



[Table/Fig-2]: Showing body segments and oral hooks of larva of *Oestrus ovis*

On slit lamp examination, approximately 1mm long translucent organisms with black heads were seen, moving over the conjunctiva in the right eye. The patient was told about the possibility of the presence of larvae and he was advised a detailed examination under a microscope, for which his consent was taken. On examination, the larvae were noticed to move freely over the bulbar and the palpebral conjunctiva. Three larvae were removed by using a sterile plain fine forceps under topical anaesthesia and they were sent to the Microbiology Department for identification. The next day, under a short general anaesthesia, the right lower fornix was examined thoroughly for larvae, after eversion with Desmane's lid retractor. The upper fornix was also examined after a double eversion. No larvae were seen. A thorough eye wash was given beneath the upper palpebral conjunctiva. The other eye was also examined for larvae.

In the microbiology laboratory, microscopy was done. The larvae were identified as the larvae of *Oestrus ovis* (sheep nasal botfly). The larvae were characterized by a pair of sharp, dark brown, oral hooks which were connected to the large internal cephalopharyngeal skeleton and by tufts of numerous brown hooks on the anterior margins of each body segment [Table/Fig-1 and 2]. After the removal of the larvae, the patient was treated with oral antibiotics and anti inflammatory drugs along with a local patch of ciprofloxacin on the right eye. The patient was discharged with an instruction to attend a follow up examination.

DISCUSSION

Human Ophthalmomyiasis was first reported by Keyt in the year 1900 [5] and later on, from India by Elliot in 1910 [6]. This can be caused by sheep bot fly larvae (*Oestrus ovis*). Other species of flies such as the human bot fly (*Dermatobia hominis*), the screw worm fly (*Phaenicia lucilia*, *Chrysomya benziana*) and the cattle bot fly (*Hypoderma bovis*) can also cause Ophthalmomyiasis [7,8].

The female *Oestrus ovis* is a large, dark, gray coloured fly with dark spots on the dorsum of the thorax and the abdomen. The sheep bot fly larvae of *Oestrus ovis* are obligate parasites of the eyes, ears, nose and the skin of sheeps and goats. The larvae are translucent and 6.8–1mm in size, which makes it difficult to detect them by the naked eye. They can be visualized with the help of a slit lamp, although they usually avoid the beams of light. These larvae can be identified by the dark mouth claws and the active vermiform movements of their bodies against the conjunctiva [2,8-10].

These larvae can penetrate the intact skin and the conjunctival mucous membrane. Their infestation occurs through the contamin-

ated hands of patients themselves after they handle infested cattle or the fly itself. Beneath the skin, the larvae begin eating the tissues and they grow into maggots, which is potentially destructive [11].

A follow up examination is advisable for the patients, to rule out the complication of Ophthalmomyiasis externa or the existence of additional larvae.

KEY MESSAGE

Ophthalmomyiasis externa is a potentially dangerous condition, for which an early and a prompt diagnosis and management is essential. In the differential diagnosis of acute conjunctivitis, this condition should be considered [12]. In the tropical countries, large populations of flies are common. This emphasizes the importance of hand hygiene and sanitation. This also illustrates the need of a timely and correct diagnosis and management of Ophthalmomyiasis externa.

REFERENCES

- [1] Gopalakrishnan S, Srinivasan R, Saxena SK, Sanmugapriya J. Myiasis in different types of carcinoma cases in southern India. *Indian J Med Microbiol*. 2008; 26: 189–92.
- [2] Cameron JA, Shoukrey NM, Al Garni AA. Conjunctival Ophthalmomyiasis which was caused by sheep nasal bot fly (*Oestrus ovis*). *Ann J Ophthalmol*. 1991; 112: 331–34.
- [3] Risco MR, Al Dosari F, Millar L. Sheep nasal botfly (*Oestrus ovis*) larvae infestation of the conjunctiva. *Arch Ophthalmol*. 1995; 113: 529–30.
- [4] Siguke E, Beebe WE, Gander RM, Cavaroti D, Southern PM. A case report: Ophthalmomyiasis externa in Dallas County, Texas. *The Am J Trop Med Hyg*. 2003; 68: 46–47.
- [5] Keyt FT (1900) quoted by: Sivaramasubramanyam P, Sadanand AV. Ophthalmomyiasis. *Brit J Ophthalmol*. 1968; 52: 64.
- [6] Elliot RH (1910) quoted by: Sivaramasubramanyam P, Sadanand AV. Ophthalmomyiasis. *Brit J Ophthalmol*. 1968; 52: 64.
- [7] Sachdev MS, Kumar H, Roop, Jain AK, Arora R, Dada VK. Destructive ocular myiasis in a non compromised host. *Indian J Ophthalmol*. 1990; 38: 184–86.
- [8] Huynh N, Dolan B et al. Management of screw worm Ophthalmomyiasis externa. *Br J Ophthalmol*. 2005; 89: 1377–78.
- [9] Stulting AA, Meyer H. External Ophthalmomyiasis which was caused by *Oestrus ovis*. *S Afr Med J*. 1981; 31: 709–10.
- [10] Harvey JT. Sheep botfly Ophthalmomyiasis externa. *Can J Ophthalmol*. 1986; 21: 92–95.
- [11] Mathur SP, Makhija JM. Invasion of the orbit by maggots. *Brit J Ophthalmol*. 1967; 51: 406.
- [12] Dunban J, Cooper B, Hodgetts T, Yskandar H, Theil PV, Whelan S, Taylor J, Woods DR. An outbreak of human external Ophthalmomyiasis which was caused by *Oestrus ovis* in southern Afganistan. *Clin Infect Dis*. 2008; 46: e124–e26.

AUTHOR(S):

1. Dr. Seema Bose
2. Dr. Santosh Saini
3. Dr. Rekha Barapatre
4. Dr. Stephen Mathew

PARTICULARS OF CONTRIBUTORS:

1. Professor of Microbiology.
2. Professor & Head, Microbiology.
3. Postgraduate Student, Microbiology.
4. Postgraduate Student, Microbiology.

NAME OF DEPARTMENT(S)/INSTITUTION(S) TO WHICH THE WORK IS ATTRIBUTED:

Rural Medical College, Loni, Ahmednagar, Maharashtra, India.

NAME, ADDRESS, E-MAIL ID OF THE CORRESPONDING AUTHOR:

Dr. Seema Bose
Professor, Department of Microbiology,
Rural Medical College,
Loni – BK, Ahmednagar,
Maharashtra, India - 413736.
Phone: +919665044401
E-mail: drseema1ghosh@gmail.com

FINANCIAL OR OTHER COMPETING INTERESTS:

None.

Date of Submission: **Jan 21, 2012**
Date of Peer Review: **Apr 09, 2012**
Date of Acceptance: **Jun 29, 2012**
Date of Publishing: **Aug 10, 2012**